

## Short Communication

# COVID-19 mRNA vaccine-associated encephalopathy, myocarditis, and thrombocytopenia with excellent response to methylprednisolone: A case report

Md Asaduzzaman<sup>\*</sup>, Bidrum Purkayastha, M. M. Jahangir Alam, Shishir Ranjan Chakraborty, Soumitra Roy, Nasad Ahmed

Department of Medicine, Sylhet MAG Osmani Medical College Hospital, Sylhet 3100, Bangladesh



## ARTICLE INFO

## Keywords:

Pfizer-BioNTech mRNA vaccine (BNT162b2)  
Vaccine-associated encephalopathy  
Myocarditis  
Thrombocytopenia  
SARS-CoV-2  
Case report

## ABSTRACT

**Introduction:** Large-scale vaccination is considered one of the most effective strategies to control the pandemic of COVID-19. Since its start, different complications have been described thought to be related to vaccination. Here, we present a rare case where encephalopathy, myocarditis, and thrombocytopenia developed simultaneously following the second dose of Pfizer-BioNTech mRNA vaccine (BNT162b2).

**Case presentation:** A 15-years-old female presented with fever, altered consciousness, and convulsions after taking the second shot of the vaccine. Clinical and laboratory workup was notable for the presence of thrombocytopenia and myocarditis. No alternative causes of encephalitis were found. The patient responded significantly to methylprednisolone suggesting underlying immune pathogenesis responsible for the clinical features. The diagnostic criteria for possible autoimmune encephalitis were also fulfilled.

**Conclusion:** Although rare, the clinician should be aware of the possible adverse events following COVID-19 vaccination. Further research with large pooled data is needed to get more insight into its pathogenesis and causal relationship.

## 1. Introduction

Since the emergence of SARS-CoV-2, the world has been greatly affected by the devastating pandemic of COVID-19 which has already taken the lives of millions of people. The evolving nature of COVID-19 disease has imposed a huge challenge on the development of effective treatment. Like any other infectious disease, vaccine is the backbone of controlling the rapid spread and fatality of COVID-19. Consequently, the world has seen the development of vaccines at an unprecedented speed and scale against this virus following successful clinical trials and approval by the regulatory bodies. A global mass vaccination campaign is underway with an all-out effort. As billions of people are getting vaccinated, it is not surprising that vaccine-related adverse events are coming into focus and being reported in the scientific literature. Although rare, several cardiac, neurological, and hematological complications (Fazlollahi et al., 2021; Goss et al., 2021; Al-Ali et al., 2022) have been described following receipt of the COVID-19 vaccine. However, the causal relationship is not yet established. Here we report a case

of COVID-19 mRNA Pfizer- BioNTech vaccine-associated encephalopathy, myocarditis, and thrombocytopenia following the second dose of vaccine which responded dramatically to methylprednisolone.

## 2. Case presentation

A 15-year-old girl was admitted to a tertiary care hospital with complaints of fever and diarrhea 1 day after receiving the second dose of Pfizer BioNTech (BNT162b2) COVID-19 vaccine. Her 1st dose of the same vaccine given 2 months earlier was uneventful. On admission, she was agitated but well conscious and oriented. The recorded temperature was 101 °F. The pupil was normal in size and reacted to light normally. There was no purpura or ecchymosis anywhere in the skin or oral cavity. The patient was dehydrated but not icteric. Blood pressure was 130/70 mmHg without any postural drop. Jugular venous pressure (JVP) was not raised. There was carpopedal spasm in both hands. She did not have any form of movement disorder like chorea, stereotypies and dystonia, and tremor. Delirium, hallucinations, and amnesia were absent. Her

<sup>\*</sup> Corresponding author at: Assistant Registrar (Hematology), Sylhet MAG Osmani Medical College Hospital, Sylhet 3100, Bangladesh.

E-mail addresses: [asad\\_somc@yahoo.com](mailto:asad_somc@yahoo.com) (M. Asaduzzaman), [miaohalum@gmail.com](mailto:miaohalum@gmail.com) (B. Purkayastha), [mmjalam@gmail.com](mailto:mmjalam@gmail.com) (M.M.J. Alam), [chakrabortysrdr@gmail.com](mailto:chakrabortysrdr@gmail.com) (S.R. Chakraborty), [dr.soumitra68@gmail.com](mailto:dr.soumitra68@gmail.com) (S. Roy), [nasadahmed@gmail.com](mailto:nasadahmed@gmail.com) (N. Ahmed).

<https://doi.org/10.1016/j.jneuroim.2022.577883>

Received 20 March 2022; Received in revised form 15 April 2022; Accepted 4 May 2022

Available online 8 May 2022

0165-5728/© 2022 Elsevier B.V. All rights reserved.

parents denied any history of malignancy diagnosed previously. Signs of meningeal irritation were absent. Fundoscopy excluded the presence of papilloedema. A lumbar puncture was done which reveals a clear cerebrospinal Fluid (CSF) and the sample was sent for laboratory analysis. Then a clinical diagnosis of encephalopathy was made and treatment was started with intravenous (IV) fluid, IV Calcium gluconate, antiviral (Acyclovir, 500 mg 8 hourly), and antibiotics (Ceftriaxone, 2 g 12 hourly) with other supportive measures as well.

The next day, the patient develops altered consciousness, and then she became unconscious. The clinical course was further complicated by several attacks of convulsions. She was then shifted to ICU for better monitoring. Based on her clinical manifestations, temporal relationship with vaccination, and lack of response to antiviral, a diagnosis of autoimmune encephalopathy was suspected. We then stopped antiviral and antibiotic therapy and started injectable methylprednisolone (1 g/day) on that day and continued for the next 2 days. The patient showed significant improvement in neurological status with a gradual return of consciousness level and cessation of convulsion. Over the next few days, the patient started to take her meal by herself. She had difficulty with walking which was improved with physiotherapy.

Initial full blood count was remarkable for marked thrombocytopenia. Renal and hepatic function was normal. Serum calcium was low. Blood glucose, serum albumin, and electrolytes were within the normal range. The level of c-reactive protein (CRP) and d-dimer were elevated while ferritin level was normal. Initial ECG showed prolongation of the QTc interval. Chest X-ray was normal. Urine microscopy was normal and

RT-PCR for SARS-CoV-2 was negative (Table 1).

CSF analysis revealed a raised protein level with pleocytosis and normal glucose level. CSF was negative for *Mycobacterium tuberculosis*, Herpes Simplex Virus, Japanese encephalitis (JE) virus, Nipah virus, and syphilis (Table 1). Magnetic resonance imaging (MRI) of the brain did not reveal any recent or old abnormality (Fig. 1).

On the 6th day following admission, the patient developed palpitation but without any chest pain or respiratory distress. Pulse rate was 100 beats per minute and Blood pressure was 90/60 mmHg. JVP was not raised. Cardiovascular system examination reveals a normal apex beat that is not displaced. No murmur and pericardial friction rub were audible and the lung base was clear on auscultation. ECG shows sinus tachycardia, non-specific ST-segment changes, and diffuse T wave inversion. Troponin I was elevated (0.406 ng/ml). Other cardiac biomarkers like cardiac troponin T (cTnT), Creatine kinase (CK) and MB isoenzyme of CK (CK-MB) were also elevated (Table 1). Subsequently, an echocardiogram was performed and it showed a hypokinetic anterior wall with reduced ejection fraction. (EF = 46%). A clinical diagnosis of myocarditis was taken into consideration. Echocardiography was repeated after 3 weeks and it shows an ejection fraction of 64% with no regional wall motion abnormality.

This case has been reported to the national vaccine adverse event reporting system.

**Table 1**  
Time trends of investigations.

Name	Day 2	Day 3	Day 4	Day 6	Day 11
White-cell count ( $\times 10^9/L$ )	11.4	9.30	5.60	9.07	13.78
Red-cell count ( $\times 10^9/L$ )	4.6	4.08	3.93	4.42	4.15
Platelet count ( $\times 10^9/L$ )	81.3	40	60	95	238
Peripheral blood film (PBF)	Normal red blood cell morphology, Normal white blood cell morphology, Decreased platelet count				
S. creatinine (mg/dl)	1.64			0.98	
S. calcium (mg/dl)	6.02	7.02	7.16	6.92	8.25
S. Albumin (gm/dl)	3.85				3.56
S. magnesium (mg/dl)	2.1			2.2	
CSF study	Color- clear Protein- 67.7 mg/dl Glucose- 88 mg/dl Total cell-12/mm <sup>3</sup> (all are lymphocytes). PCR for Herpes Simplex Virus, mycobacterium tuberculosis, Japanese encephalitis (JE) virus, Nipah virus- negative VDRL- negative				
S. electrolytes		Na- 140 K-4.48 Cl- 108.3 CO2-23			
Urine microscopy	No abnormality detected				
PCR for SARS-CoV-2	Negative				
Prothrombin time			14 s (INR-1.20)		
CRP (mg/l)				29.4 (ref: 3)	5
Ferritin (ng/ml)				399.7	
D- dimer (mg/l)				2.84 (ref: 0 - 0.5)	
Echocardiography				Anterior wall hypokinetic, Mild LV systolic dysfunction, EF: 46%	
Troponin I (ng/ml)				0.406 (ref: 0 - 0.04)	
Cardiac Troponin T (ng/ml)				0.60 (Ref: < 0.1 ng/ml)	
Creatine phosphokinase (CK)				330 U/L (ref: 22 - 198 U/L)	
MB isoenzyme (CK-MB)				56 IU/L (ref: 5 - 25 IU/L)	
NT- pro BNP (pg/ml)				1744.2 (ref: up to 125)	

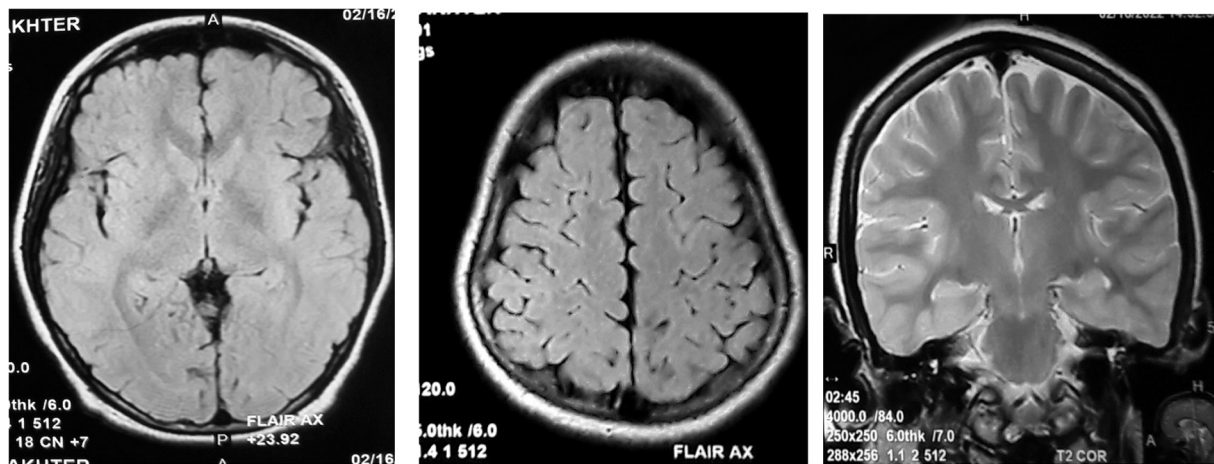


Fig. 1. MRI brain reveals no abnormality in axial slice of the basal and parietal FLAIR and coronal slice around the hippocampus.

### 2.1. Follow-up and outcomes

The patient was followed for 4 weeks so far. Her neurological condition improved. No adverse and unanticipated events developed during this period.

### 3. Discussion

Since the beginning of the COVID-19 pandemic, a range of neurological disorders as a manifestation of SARS-CoV-2 infection has been described (Patone et al., 2021). Similar to other coronaviruses, SARS-CoV-2 can invade the CNS through direct hematogenous spread or neural dissemination (Yu et al., 2020). However, SARS CoV-2 was not detected in the CSF of patients who presented with severe neurological manifestations. Rather a Cytokine release syndrome (CRS) and the consequent hyperinflammatory response was found to be the driver of neurological complication in COVID-19. Moreover, marked elevation of serum IL-6, evidence of increased blood-brain barrier (BBB) permeability, a rise in serum levels of the S100B protein, an astroglial marker, and good response to steroids point to an underlying autoimmune aetiology (Perrin et al., 2021). A large post-mortem case series found no evidence for neuronal damage directly attributable to SARS-CoV-2, which might be due to additional factors such as cytokine storm, neuro-immune stimulation, and systemic SARS-CoV-2 infection (Matschke et al., 2020).

A spectrum of neurological conditions can develop after COVID-19 vaccination, ranging from mild symptoms, like fever with chills, headache, fatigue, myalgia, and arthralgia to severe symptoms, like encephalitis, acute disseminated encephalomyelitis, Cerebral venous thrombosis (CVST), Guillain-Barré syndrome (GBS) and stroke (Garg and Paliwal, 2022). When compared with neurological complications that develop after SARS-CoV-2 infection, the incidence rate ratio (IRR) was far less following COVID-19 vaccination (Patone et al., 2021).

The exact aetiology is not proven yet, but it is hypothesized that spike protein expression by recipient cells following translation of vaccine mRNA triggers the same inflammatory cascade as COVID-19 infection and leads to neurological complications (Liu et al., 2021). An elevated level of neuroinflammatory mediators was also detected in the CSF sample of such patients (Liu et al., 2021; Baldelli et al., 2021). Besides, adjuvants of the BNT162b2 vaccine have also been implicated as a trigger for immune reactions (Vera-Lastra et al., 2021).

The characteristics clinical features, deterioration while on antiviral and antibiotics, suggestive laboratory and imaging findings, and prompt response to methylprednisolone clues to an underlying immune aetiology. Subacute onset of the illness, development of seizures not explained by a previously known seizure, presence of CSF pleocytosis

and reasonable exclusion of alternative causes after extensive diagnostic workup meets the Graus diagnostic criteria for possible autoimmune encephalitis (Graus et al., 2016). Based on the temporal association between vaccination and symptom onset, a diagnosis of vaccine-associated encephalopathy was considered. It is to be mentioned that some laboratory tests like anti-COVID vaccination titer, and anti-neuronal antibodies should have been done but were not possible due to restricted access in the country.

Thrombocytopenia has been reported after several vaccines, like MMR, Haemophilus influenza, hepatitis B virus, human papillomavirus (HPV), varicella-zoster, pneumococcus, and polio (Woo et al., 2011). The underlying pathogenesis is likely to be immune-mediated as antibodies have been detected on platelets in a significant number of cases (Cecinati et al., 2013). A recent study that analyzed the data of thrombocytopenia after receipt of mRNA COVID-19 vaccines reported to the Vaccine Adverse Event Reporting System (VAERS) identified fifteen cases of thrombocytopenia among 18,841,309 doses of Pfizer-BioNTech COVID-19 Vaccine and 13 cases among 16,260,102 doses of Moderna COVID-19 Vaccine which is fewer when considering the background rate of ITP and thus do not suggest a safety concern attributable to COVID-19 vaccination (Welsh et al., 2021). In our patient, thrombocytopenia was observed on 2nd day of vaccination. Immune-mediated thrombocytopenia usually requires a longer time to develop. As our patient had a history of COVID-19 infection a few months back, So, the earlier onset of thrombocytopenia in our case could be explained by prior sensitization with SARS-CoV-2 infection. A rapid rise in platelet counts after starting methylprednisolone also suggests an autoimmune process.

Although we could not perform cardiac Magnetic resonance imaging (MRI) because our priority was to stabilize the patient first, the clinical features and characteristic ECG and echocardiogram findings were consistent with the clinical diagnosis of myocarditis. Several cases of myocarditis after COVID-19 vaccination have been reported (Montgomery et al., 2021; Witberg et al., 2021). Furthermore, it has been seen that most cases of myocarditis developed after the second dose of vaccine which is consistent with our findings. The possible mechanisms are mRNA immune reactivity, antibodies to SARS-CoV-2 spike glycoproteins cross-reacting with myocardial contractile proteins, and hormonal differences. All of these can be influenced by immune-genetic background (Heymans and Cooper, 2022).

This report has got some limitations. First, the temporal relationship between vaccination and the development of adverse events described here does not establish a causal relationship. Second, we couldn't do antibody testing for autoimmune encephalitis due to unavailability.

#### 4. Conclusion

To the best of our knowledge, this is the first reported case who developed encephalopathy, myocarditis, and thrombocytopenia simultaneously after the second dose of Pfizer-BioNTech mRNA vaccine (BNT162b2) despite no adverse event after the first dose of the same vaccine. We found a good outcome of post-vaccine encephalopathy and thrombocytopenia following administration of methylprednisolone. Given the rarity of the event, more research involving more cases must be conducted to find out the exact pathogenesis behind this neurological and cardiac manifestation and the causal role of the vaccine. The clinician should be aware of the potential adverse event following COVID-19 vaccination and notify them and treat them according to the best evidence available.

#### Guidelines

The case report presentation followed CARE guidelines (Riley et al., 2017).

#### Learning points for clinicians

Clinicians should be vigilant in patients presenting with acute cardiac and neurologic disorders after receiving the shot of the COVID-19 vaccine. A high index of suspicion can help in the early identification and prompt management of these conditions.

#### Patient perspective

“My illness started as a fever and diarrhea. I was feeling restless. On the next day, I could not recognize the people around me. I could not remember what happened to me afterward. I remember the doctors, nurses, other supporting staff and they took excellent care of me. I am grateful to all of them.”

#### Ethical approval

Not required.

#### Consent

Written informed consent was obtained from the patient's father for publication of this case report and the accompanying image. A copy of the written consent is available for review by the Editor-in-Chief upon request.

#### Author contributions

MA: patient care, conceptualization, data gathering, literature review, manuscript writing. BP: patient care, manuscript writing. MMJA, SRC, SR, and NA: patient care, editing, and revision of the final manuscript. All authors reviewed, edited, and approved the final version of the manuscript.

#### Declaration of Competing Interest

The authors declare that they have no known competing financial interests or personal relationships that could have appeared to influence the work reported in this paper.

#### Acknowledgments

The authors are grateful for the kind permission of the patient and

her family to publish this case. We are also immensely grateful to Prof Biplob Kumar Roy (Neurologist), Dr. Mukhlasur Rahman (Cardiologist), Dr. Moinul Islam Dalim (intensivist), Dr. Mahbub Alam Jiban (Cardiologist), and Dr. Swajal Das (Radiologist) for sharing their pearls of wisdom with us during the management of this patient as well as preparing this research, and we thank three reviewers for their valuable insights.

#### References

- Al-Ali, D., Elshafeey, A., Mushannen, M., Kawas, H., Shafiq, A., Mhaimeed, N., et al., 2022. Cardiovascular and haematological events post COVID-19 vaccination: a systematic review. *J. Cell. Mol. Med.* 26 (3), 636–653. <https://doi.org/10.1111/jcmm.17137>.
- Baldelli, L., Amore, G., Montini, A., Panzera, I., Rossi, S., Cortelli, P., et al., 2021. Hyperacute reversible encephalopathy related to cytokine storm following COVID-19 vaccine. *J. Neuroimmunol.* 358 (577661), 577661. <https://doi.org/10.1016/j.jneuroim.2021.577661>.
- Cecinati, V., Principi, N., Brescia, L., Giordano, P., Esposito, S., 2013. Vaccine administration and the development of immune thrombocytopenic purpura in children. *Hum. Vaccin. Immunother.* 9 (5), 1158–1162. <https://doi.org/10.4161/hv.23601>.
- Fazlollahi, A., Zahmatyar, M., Noori, M., Nejadghaderi, S.A., Sullman, M.J.M., Shekarriz-Foumani, R., et al., 2021. Cardiac complications following mRNA COVID-19 vaccines: a systematic review of case reports and case series. *Rev. Med. Virol.* <https://doi.org/10.1002/rmv.2318>.
- Garg, R.K., Paliwal, V.K., 2022. Spectrum of neurological complications following COVID-19 vaccination. *Neurol. Sci.* 43 (1), 3–40. <https://doi.org/10.1007/s10072-021-05662-9>.
- Goss, A.L., Samudralwar, R.D., Das, R.R., Nath, A., 2021. ANA investigates: neurological complications of COVID-19 vaccines. *Ann. Neurol.* 89 (5), 856–857. <https://doi.org/10.1002/ana.26065>.
- Graus, F., Titulaer, M.J., Balu, R., Benseler, S., Bien, C.G., Cellucci, T., et al., 2016. A clinical approach to diagnosis of autoimmune encephalitis. *Lancet Neurol.* 15 (4), 391–404. [https://doi.org/10.1016/s1474-4422\(15\)00401-9](https://doi.org/10.1016/s1474-4422(15)00401-9).
- Heymans, S., Cooper, L.T., 2022. Myocarditis after COVID-19 mRNA vaccination: clinical observations and potential mechanisms. *Nat. Rev. Cardiol.* 19 (2), 75–77. <https://doi.org/10.1038/s41569-021-00662-w>.
- Liu, B.D., Ugolini, C., Jha, P., 2021. Two cases of post-Moderna COVID-19 vaccine encephalopathy associated with nonconvulsive status epilepticus. *Cureus* 13 (7), e16172. <https://doi.org/10.7759/cureus.16172>.
- Matschke, J., Lütgehetmann, M., Hagel, C., Spherhake, J.P., Schröder, A.S., Edler, C., et al., 2020. Neuropathology of patients with COVID-19 in Germany: a post-mortem case series. *Lancet Neurol.* 19 (11), 919–929. [https://doi.org/10.1016/S1474-4422\(20\)30308-2](https://doi.org/10.1016/S1474-4422(20)30308-2).
- Montgomery, J., Ryan, M., Engler, R., Hoffman, D., McClenathan, B., Collins, L., et al., 2021. Myocarditis following immunization with mRNA COVID-19 vaccines in members of the US military. *JAMA Cardiol.* 6 (10), 1202–1206. <https://doi.org/10.1001/jamacardio.2021.2833>.
- Patone, M., Handunnetthi, L., Saatci, D., Pan, J., Katikireddi, S.V., Razvi, S., et al., 2021. Neurological complications after first dose of COVID-19 vaccines and SARS-CoV-2 infection. *Nat. Med.* 27 (12), 2144–2153. <https://doi.org/10.1038/s41591-021-01556-7>.
- Perrin, P., Collongues, N., Baloglu, S., Bedo, D., Bassand, X., Lavaux, T., et al., 2021. Cytokine release syndrome-associated encephalopathy in patients with COVID-19. *Eur. J. Neurol.* 28 (1), 248–258. <https://doi.org/10.1111/ene.14491>.
- Riley, D.S., Barber, M.S., Kienle, G.S., Aronson, J.K., von Schoen-Angerer, T., Tugwell, P., et al., 2017. CARE guidelines for case reports: explanation and elaboration document. *J. Clin. Epidemiol.* 89, 218–235. <https://doi.org/10.1016/j.jclinepi.2017.04.026>.
- Vera-Lastra, O., Ordinola Navarro, A., Cruz Domiguez, M.P., Medina, G., Sánchez Valadez, T.I., Jara, L.J., 2021. Two cases of graves' disease following SARS-CoV-2 vaccination: an autoimmune/inflammatory syndrome induced by adjuvants. *Thyroid* 31 (9), 1436–1439. <https://doi.org/10.1089/thy.2021.0142>.
- Welsh, K.J., Baumblatt, J., Chege, W., Goud, R., Nair, N., 2021. Thrombocytopenia including immune thrombocytopenia after receipt of mRNA COVID-19 vaccines reported to the vaccine adverse event reporting system (VAERS). *Vaccine* 39 (25), 3329–3332. <https://doi.org/10.1016/j.vaccine.2021.04.054>.
- Witberg, G., Barda, N., Hoss, S., Richter, I., Wiessman, M., Aviv, Y., et al., 2021. Myocarditis after Covid-19 vaccination in a large health care organization. *N. Engl. J. Med.* 385 (23), 2132–2139. <https://doi.org/10.1056/NEJMoa2110737>.
- Woo, E.J., Wise, R.P., Menschik, D., Shadomy, S.V., Iskander, J., Beeler, J., et al., 2011. Thrombocytopenia after vaccination: case reports to the US vaccine adverse event reporting system, 1990–2008. *Vaccine* 29 (6), 1319–1323. <https://doi.org/10.1016/j.vaccine.2010.11.051>.
- Yu, H., Sun, T., Feng, J., 2020. Complications and pathophysiology of COVID-19 in the nervous system. *Front. Neurol.* 11, 573421. <https://doi.org/10.3389/fneur.2020.573421>.